

Early Treatment of a Class II, Division 2 Malocclusion with the Trainer for Kids (T4K): A Case Report

Ramirez-Yañez, German O * / Faria, Paulo **

This paper reports a Class II, division 2 malocclusion case successfully treated at an early age and in a relatively short period of time using the Trainer for Kids (T4K), a prefabricated functional appliance. Skeletal changes observed in the before and after treatment cephalic radiographs were compared with the expected changes produced by the patient's natural growth. The functional appliance's effects resulting in the outcomes observed in this clinical case, as well as the importance of identifying the etiological factors when treating a malocclusion will be discussed.

Keywords: Mixed dentition, orthopedics, class II division 2, TK4.

J Clin Pediatr Dent 32(4): 325–330, 2008

INTRODUCTION

A class II, division 2 malocclusion is a skeletal and dental problem consisting of a deep bite and retroclined maxillary central incisors. Correction of this type of malocclusion may be performed with either fixed orthodontics or functional appliances. As there is no scientific evidence discouraging the early correction of this problem,¹ some authors recommend treatment during the mixed dentition.²⁻⁴

The skeletal and dental effects produced by functional appliances are still controversial. It appears that these appliances produce neuromuscular changes^{5,6} that lead to morphological modifications in the craniofacial complex.^{3,4,7,8} Another point of discussion is the prediction of both, the success and the duration of treatment for Class II malocclusions. Successful outcomes for treatment with functional appliances have been associated with the patient's age and the severity of the malocclusion.⁹⁻¹¹ The activity of the facial muscles, particularly the lip muscles, have also been reported to influence the response and duration of treatment for Class II malocclusions. Between the two types of Class II malocclusions, less time may be required to treat a division 2 than a division 1 malocclusion.²

The Trainer for Kids (T4K™, Myofunctional Research Co, Australia) is a polyurethane pre-fabricated functional appliance, composed of various elements¹² that stimulate the facial, masticatory and tongue muscles. This functional appliance changes the posture of the mandible into a forward position,¹³ and stimulates transverse development.¹⁴ Although this pre-fabricated functional appliance has demonstrated to produce skeletal and dental improvement in Class II, division 1 malocclusion patients,^{13,14} there are no reports using this functional appliance for the treatment of Class II, division 2 malocclusion. Thus, the purpose of this paper is to present a clinical case where a patient with Class II, division 2 malocclusion was successfully treated during the mixed dentition with the T4K in a relatively short period of time.

CASE PRESENTATION

A 10-year-old girl sought consultation because of a crowded dentition and buccally tipped maxillary lateral incisors. Clinically, she had bilateral Class II molar and canine relationship, 5 mm overjet and 95% overbite (Figure 1). During the clinical exam, hyperactivity of the chin, cheeks and lip musculature was observed. The mixed dentition analysis reported enough space to accommodate permanent premolars and canines (Figure 2). Skeletally, the McNamara's analysis confirmed a Class II inter-maxillary relationship with a reduced Sella-Nasion-Point B (SNB) angle and an increased Point A-Nasion-Point B (ANB) angle (Figure 4A and Table 1). The Sella-Nasion-Point A (SNA) angle was considered normal. The length of the mandible, distance Condylion-Gnation (Co-Gn) was reduced, as well as the position of Point A with respect to Condylion (Co-A). The anterior facial height and the distance from the Anterior Nasal Spine to Menton (ANS-Me) were also reduced. This case was diagnosed as a Disto-occlusion, Class II, division

* Ramirez-Yañez, German O. DDS, Pedo Spec, MDS, PhD Assistant Professor, Marquette University School of Dentistry, Department of Developmental Sciences, Milwaukee, WI

** Faria, Paulo. DDS, Private Practice, Sao Paulo, Brazil

Send all correspondence to: Dr. German Ramirez-Yañez, 1801 W. Wisconsin Avenue, Rm 322, Milwaukee, WI 53233, USA

Phone: + 414 2885694

Fax: + 414 288 0765.

E mail: german.ramirez@marquette.edu

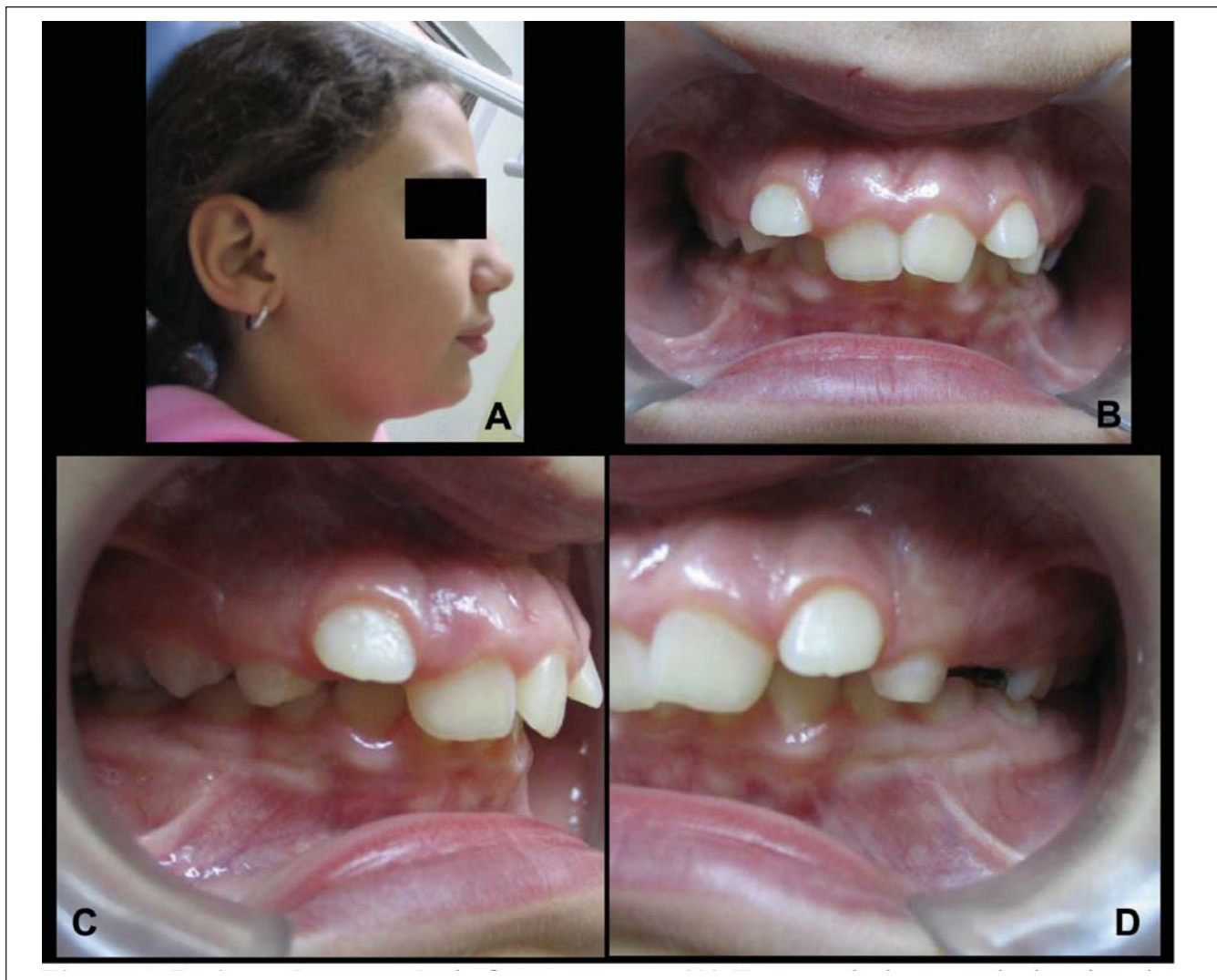

Figure 1. Patient photographs before treatment. (A) Extra-oral photograph showing the profile; (B) Occlusion frontal view; (C) Occlusion right side; and, (D) Occlusion left side.

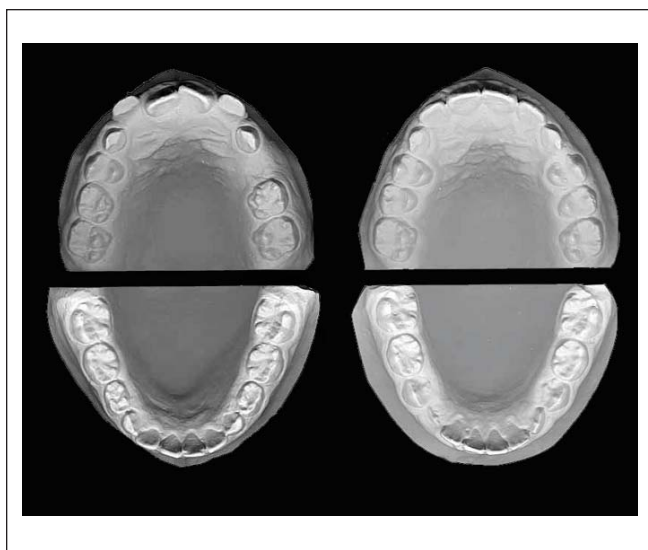

Figure 2. Study models before (A) and after (B) treatment. Sufficient space for tooth alignment from the mixed dentition analysis before treatment and, good dental alignment achieved after 12 months of treatment with the T4K.

2; deep bite with adequate transverse development.

The treatment plan aimed to reposition the mandible forward and improve tooth position. Muscular activity improvement of the facial muscles and a better posture of the lips were also pursued. Therefore, treatment was proposed in two phases: The first phase included a T4K used as recommended by the manufacturer, 1-2 hours during daytime and 10-12 hours overnight; and the second phase was programmed with fixed orthodontics starting 12-15 months later, once the mandibular position had improved with the use of the functional appliance. As explained later, the second phase of treatment was changed after observing and analyzing the results achieved during the first phase.

To analyze the results obtained during the first phase of treatment, another cephalic radiograph was taken after one year of treatment. The differences between cephalometric measurements before and after one year of treatment with the T4K were computed and compared with the expected growth naturally occurring in Brazilian females (10 to 11 years of age). The differences between the values of the per-

formed cephalometric measurements were compared with normative data from a Brazilian population.¹⁵

RESULTS

After 12 months of treatment with the T4K, an improvement in the inter-maxillary relationship was clinically observed, the deep-bite was corrected and a molar and canine Class I relationship was achieved (Figure 3). Tooth alignment, particularly the maxillary incisors, improved without using any other appliance. Furthermore, the hyperactivity in the facial muscles observed during the initial exam was reduced and a more balanced muscular activity was noticed.

The treatment goals were achieved within a year and further treatment became unnecessary. The clinical results were associated with skeletal improvement when initial and 12 month cephalometric measurements were compared (Figures 4 & Table 1). The SNA angle increased 0.8° and the SNB angle increased 4.5° during the treatment period. These skeletal modifications caused a reduction in the ANB angle, changing from 7.5° to 3.7° after 12 months of treatment with

the T4K. The three distances Condylion-Gnathion, Condylion-Point A and ANS-Me were also increased.

The differences between before and after treatment measurements were higher than those expected to be produced by natural growth in Brazilian females. The natural growth for the maxilla and the mandible for a 10 to 11 year old Brazilian female is expected to produce an increase of 0.2° for both SNA and SNB angles, and a reduction of 0.1° in the ANB angle. In the case here presented, point A moved forward 0.8° and point B moved 4.5° , which reduced the ANB angle by 3.8° . Additionally, the distances Co-Gn and Co-A increased 4.3 and 4.1 mm respectively, while the natural growth for those distances is expected to produce an increase of 2.8 and 1.7 mm respectively. Vertically, the ANS-Me distance increased by 3.1 mm; this is higher than that expected from natural growth (1.1 mm). The values for the cephalometric measurements performed before and after treatment, the correspondent matched values of normative data for 10 and 11 year olds and the differences between before and after treatment are shown in Table 1.

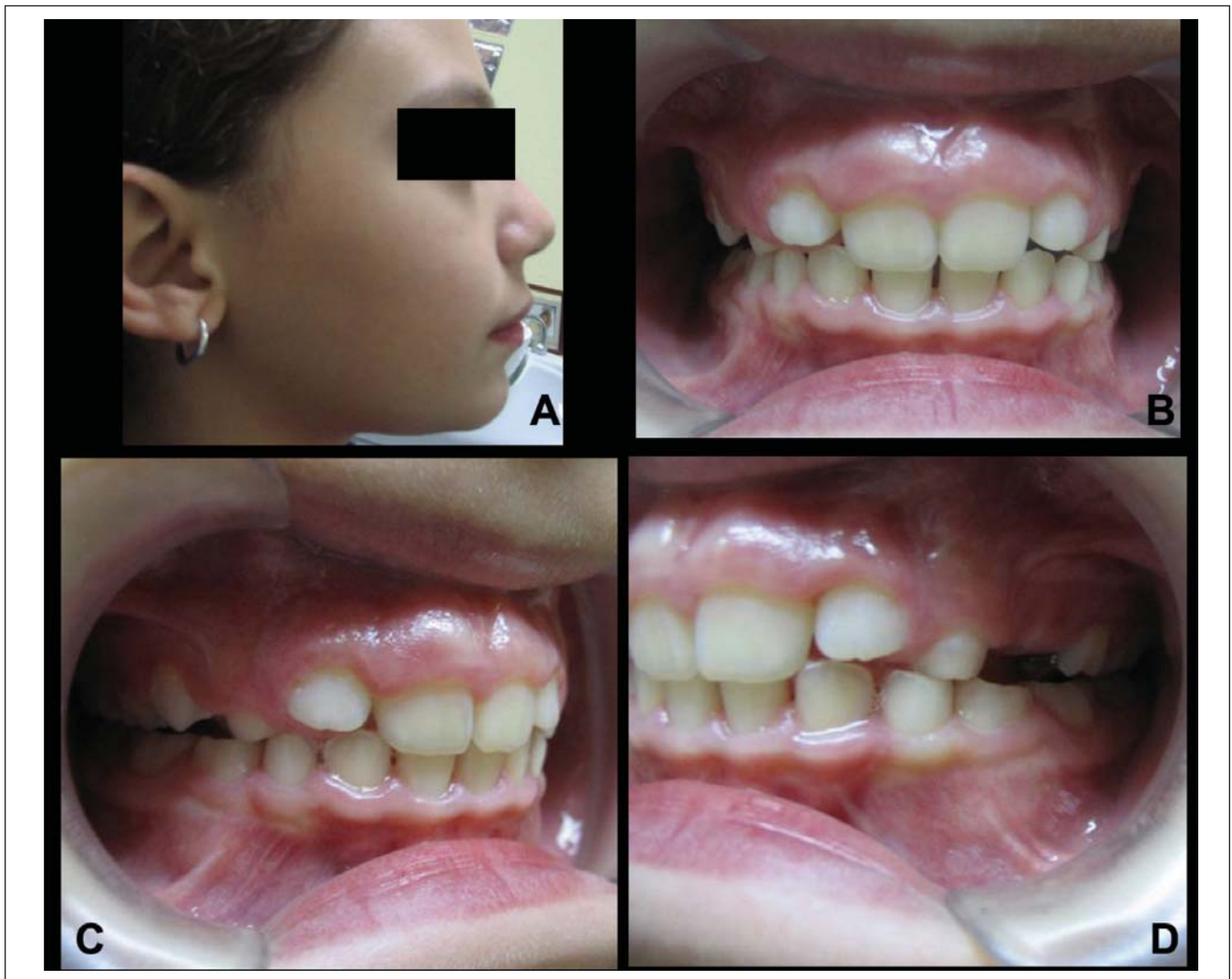

Figure 3. Patient photographs after 12 months of treatment with the T4K. (A) Extra-oral photograph showing the profile; (B) Occlusion frontal view; (C) Occlusion right side; and, (D) Occlusion left side

Table 1. Cephalometric measurements before treatment and 14 months later. Skeletal improvement observed when comparing before and after treatment measurements. Differences between measurements at the beginning and at the end of treatment were higher than those expected

Measurement	Before Treatment Age 10	After Treatment Age 11	Difference	Normal for 10 years	Normal for 11 years	Difference	Difference between Patient's and Normative Data
	years	years		Female	Female		
SNA	79.5 °	80.3 °	+ 0.8 °	81.5 °	81.7 °	+ 0.2 °	+ 0.6 °
SNB	72.1 °	76.6 °	+ 4.5 °	78.2 °	78.4 °	+ 0.2 °	+ 4.3 °
ANB	7.5 °	3.7 °	- 3.8 °	3.3 °	3.2 °	- 0.1 °	- 3.7 °
Co - Gn	103.2 mm	107.5 mm	+ 4.3 mm	106.4 mm	109.2 mm	+ 2.8 mm	+ 1.5 mm
Co - A	83.2 mm	87.3 mm	+ 4.1 mm	83.9 mm	85.6 mm	+ 1.7 mm	+ 2.4 mm
ANS - Me	61.8 mm	64.9 mm	+ 3.1 mm	61.9 mm	63.0 mm	+ 1.1 mm	+ 2.0 mm

After one year of treatment, the improvement in the patient's occlusion was better than expected. Therefore, the patient decided not to continue with the second phase of treatment, the treatment plan was modified, and the patient continued using the T4K over 6 additional months. After 18 months of treatment with the functional appliance, the active treatment was considered finished and the patient was advised not to use the T4K anymore. The one-year follow up showed a stable result and no signs of relapse were observed (Figure 5).

DISCUSSION

The clinical case presented, shows that the T4K was successfully used to treat the Class II, division 2 malocclusion and the deep bite in this patient in a short period of time. The cephalometry demonstrated that the SNA, SNB and ANB angles, as well as the Co-Gn, Co-A and ANS-Me distances were positively modified during the 12 months of treatment,

producing higher numbers than those expected from natural growth. This means that the maxilla grew forward; the mandible was repositioned forward, by both, mandibular growth and the inferior anterior facial height increase. A change in mandibular posture and an increase in the SNB angle when treating class II, division 1 malocclusions with the T4K has been demonstrated.¹³ However, there are no studies reporting the possibility of mandibular growth stimulation in young patients when using the TK4. In the case here presented, mandibular growth was cephalometrically determined as a direct effect of treatment with the functional appliance. Nevertheless, further clinical studies are needed to determine if this functional appliance can consistently stimulate mandibular growth when treating class II malocclusions.

Another interesting observation in this case was the clinical and skeletal improvement in the vertical dimension. A deep bite was diagnosed before treatment and clinically the

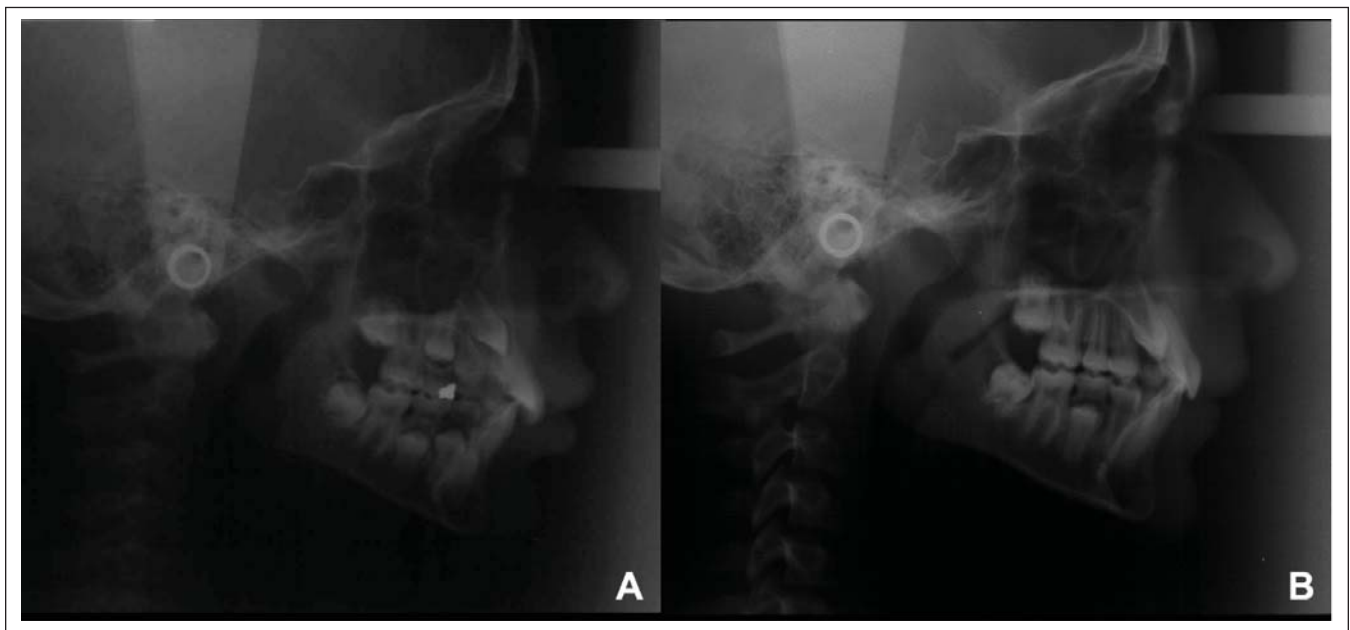


Figure 4. Cephalograms before treatment (A) and 12 months later (B).

vertical dimension rose with treatment into a normal overbite. This clinical result was associated with skeletal changes. The ANS-Me distance increased more than that expected to be produced by natural growth during the treatment period. Therefore, that clinical result in this case is mainly due to a change of posture of the mandible associated with mandibular growth and an increase in vertical dimension directly caused by the use of the functional appliance.

This clinical case was diagnosed as a Class II, division 2 malocclusion with deep bite. The diagnosis may include the type of malocclusion, but it is also necessary to determine the primary and associated factors causing the malocclusion.¹⁶⁻¹⁸ The influence of imbalances in the masticatory and facial muscles have been described in the literature.¹⁷ In this clinical case the T4K helped to balance both, the masticatory and the facial muscular forces. Since the equilibrium of the muscular force delivered to the craneo-cervico-mandibular system was regained through the action of the features included in the T4K, the teeth could align and move into a better position.²⁰⁻²²

The aims of treatment in this patient were achieved in a relatively short period of time. However, it does not mean that treatment with the T4K will produce similar results in all patients with this type of malocclusion. Patients with a class II, division 2 malocclusion have been associated with hypertonicity of the lip muscles and treatment response appears to be more favorable in those patients.² It is difficult to determine the reasons of the quick treatment success in the case here presented. It could be because the aim of the treatment focused on both, correcting the malocclusion and balancing the muscular activity,¹⁹ because Class II, division 2 malocclusion patients may respond better and faster,^{2,23} or because treatment was performed during a period of accelerated growth.^{24,25} This paper only reports one patient and, the biological response to treatment from one patient to another may vary. Controlled studies with an appropriate sample have to be performed to determine the modus operandi of the T4K in this type of malocclusion.

CONCLUSIONS

This paper shows through a clinical case that the T4K may be a useful method to treat Class II, division 2 malocclusions at an early age as it has been demonstrated for Class II, division 1 malocclusions. The results in this patient suggest that the T4K may stimulate mandibular growth and increase the vertical dimension. It is important for the clinician to identify the primary and associated factors causing the malocclusion and properly treat them by balancing the force delivered on the various components of the craneo-cervico-mandibular system. This may result in a faster treatment and a more stable result.

REFERENCES

- Millet DT, Cunningham SJ, O'Brien KD, Benson P, Williams A, de Oliveira CM. Orthodontic treatment for deep bite and retroclined upper front teeth in children. *Cochrane Database Syst Rev*, 18: CD005972. 2006.
- Posen AL. The application of quantitative perioral assessment to orthodontic case analysis and treating planning. *Angle Orthod*, 46: 118-143, 1976.
- Cozza P, Baccetti T, Franchi L, De Toffol L, McNamara JA Jr. Mandibular changes produced by functional appliances in Class II malocclusion: a systematic review. *Am J Orthod Dentofac Orthop*, 129: 118-122, 2006.
- Antonarakis GS, Kiliaridis S. Short-term anteroposterior treatment effects of functional appliances and extraoral traction on class II malocclusion. A meta-analysis. *Angle Orthod*, 77: 907-914, 2007.
- Hiyama S, Ono PT, Ishiwata Y, Kuroda T, McNamara JA Jr. Neuromuscular and skeletal adaptations following mandibular forward positioning induced by the Herbst appliance. *Angle Orthod*, 70: 442-453, 2000.
- Du X, Hagg U. Muscular adaptation to gradual advancement of the mandible. *Angle Orthod*, 73: 525-531, 2003.
- Nelson C, Harkness M, Herbison P. Mandibular changes during functional appliance treatment. *Am J Orthod Dentofac Orthop*, 104: 153-161, 1993.
- Toth LR, McNamara JA. Treatment effects produced by the twin-block appliance and the FR-2 appliance of Frankel compared with and untreated Class II sample. *Am J Orthod Dentofac Orthop*, 116: 507-609, 1999.
- Barton S, Cook PA. Predicting functional appliance treatment outcome in Class II malocclusions: A review. *Am J Orthod Dentofac Orthod*, 112: 282-286, 1997.
- Jacobs T, Sawaengkit P. National Institute of Dental and Craniofacial Research efficacy trials of bionator class II treatment: a review. *Angle Orthod*, 72: 571-575, 2002.
- Popowicz K, Nebbe B, Heo G, Glover KE, Major PW. Predictors for Class II treatment duration. *Am J Orthod Dentofac Orthop*, 127: 293-300, 2005.
- Quadrelli C, Gheorgiu M, Marchetti C, Ghiglione V. Early myofunctional approach to skeletal Class II. *Mondo Orthod*, 2: 109-122, 2002.
- Usumez S, Uysal T, Sari Z, Basciftci FA, Karaman AI, Guray E. The effects of early preorthodontic Trainer treatment on Class II, division 1 patients. *Angle Orthod*, 74: 605-609, 2004.
- Ramirez-Yañez G, Sidlauskas A, Junior E, Fluter J. Dimensional changes in dental arches after treatment with a prefabricated functional appliance. *J Clin Pediatr Dent*, 31: 279-283, 2007.
- Martins D, Janson G, de Almeida R, Pinzan A, Henriques JF, de Freitas MR. Atlas de crescimento craniofacial. Editora Santos. Sao Paulo, Brazil, 1998.
- Graber T. The three M's: muscles, malformation and malocclusion. *Am J Orthod Dentofac Orthop*, 49: 418-450, 1963.
- Bakke M, Moller E. Occlusion, malocclusion and craniomandibular function. In: Current controversies in orthodontics. Melsen B (Ed). Quintessence, Chicago. pages 77-102, 1991.
- Simoes WA. Insights into maxillary and mandibular growth for a better practice. *J Clin Pediatr Dent*, 21: 1-8, 1996.
- Ramirez-Yañez GO, Farrell C. Soft tissue dysfunction: A missing clue when treating malocclusions. *Int J Jaw Func Orthop*, 1: 483-494, 2005.
- Vargervik K. Morphologic evidence of muscle influence on dental arch width. *Am J Orthod*, 76: 21-28, 1979.
- Harradine NW, Kirschen RH. Lip and mentalis activity and its influence on incisor position—a quantitative electromyographic study. *Br J Orthod*, 10: 114-127, 1983.
- Jung MH, Yang WS, Nahm DS. Effects of upper lip closing force on craniofacial structures. *Am J Orthod Dentofac Orthop*, 123: 58-63, 2003.
- Posen AL. The influence of maximum perioral and tongue force on the incisor teeth. *Angle Orthod*, 42: 285-309, 1972.
- Baccetti T, Franchi L, Toth LR, McNamara JA Jr. Treatment timing for Twin-block therapy. *Am J Orthod Dentofac Orthop*, 118: 159-170, 2000.
- Faltin KJ, Faltin RM, Baccetti T, Franchi L, Ghiozzi B, McNamara JA Jr. Long-term effectiveness and treatment timing for Bionator therapy. *Angle Orthod*, 73: 221-230, 2003.

